



Minimally invasive approach for the treatment of pancreatic pseudocyst. Transgastric drainage – where we are now?

Minimalno invazivni pristup u lečenju pseudociste pankreasa. Transgastrična drenaža – gde smo sada?

Nenad Perišić*, Mihailo Bezmarević†, Radoje Doder*‡, Darko Mirković†‡,
Irina Brčerević*, Stanko Petrović*

Military Medical Academy, *Clinic for Gastroenterology, †Clinic for General Surgery,
Belgrade, Serbia; University of Defense, ‡Faculty of Medicine of the Military Medical
Academy, Belgrade, Serbia

Abstract

Introduction. Minimally invasive approach for the treatment of acute pancreatitis (AP) and its complications has proven to reduce morbidity and mortality rate, length of hospitalization and costs of treatment, and improve quality of life of the patients. This approach for the AP has been implemented in developed countries, but in our region lags behind. In this case report we presented the successful endoscopic transgastric drainage of the large pancreatic pseudocyst (PPC) developed as a complication of AP. **Case report.** A 63-years old male patient was presented with nausea and vomiting as a consequence of the compressive effects of the PPC in the body and tail of the pancreas after episode of AP. On computed tomography (CT) scan, it was shown a cystic formation in the region of the pancreatic body and tail compressing stomach which was verified on upper endoscopy. Under fluoroscopy, using lateral duodenoscope, the biliary plastic prosthesis of 12 French and 8 cm of length was placed throughout posterior stomach wall into the PPC. The intervention was finished uneventfully, without complications. On CT scan performed 7 days after procedure, the reduction of the PPC size was significant and control CT scan one month after the procedure and removal of the prosthesis showed almost complete resolution of the PPC. **Conclusion.** Endoscopic transgastric drainage is safe and effective procedure for PPCs especially when the PPC has pulsion effects on stomach wall.

Key words:

pancreatitis; acute disease; pancreatic pseudocyst; minimally invasive surgical procedures; drainage; treatment outcome.

Apstrakt

Uvod. Minimalno invazivni pristup u lečenju akutnog pankreatitisa (AP) i njegovih komplikacija dovodi do smanjenja stope morbiditeta i mortaliteta, dužine hospitalizacije i troškova lečenja i poboljšava kvalitet života bolesnika. Ovaj pristup u lečenju AP je implementiran u razvijenim zemljama, ali naš region zaostaje u njegovoj primeni. Cilj rada je bio prikaz bolesnika kod koga je učinjena uspešna endoskopska transgastrična drenaža pseudociste pankreasa (PPC) nastale usled komplikacija AP. **Prikaz bolesnika.** Muškarac, starosti 63 godine, javio se zbog mučnine i povraćanja usled kompresivnih efekata PPC u telu i repu pankreasa, a nakon ataka AP. Na kompjuterizovanoj tomografiji (CT) cistična formacija nalazila se u regiji tela i repa pankreasa sa kompresijom na želudac, što je potvrđeno gornjom endoskopijom. Pod fluoroskopijom, uz pomoć lateralnog duodenoskopa plasirana je plastična bilijarna proteza od 12 frenča, dužine 8 cm kroz zadnji zid želuca u PPC. Procedura je protekla bez komplikacija. Na CT pregledu, 7 dana nakon intervencije, potvrđeno je značajno smanjenje veličine PPC, a na kontrolnom CT pregledu, mesec dana od intervencije i odstranjenja proteze, potvrđena je skoro potpuna rezolucija PPC. **Zaključak.** Endoskopska transgastrična drenaža je sigurna i efikasna procedura u lečenju PPC, naročito kada PPC ima pulsivni efekat na zid želuca.

Ključne reči:

pankreatitis; akutna bolest; pankreas, pseudocista; hirurgija, minimalno invazivne procedure; drenaža; lečenje, ishod.

Introduction

Acute pancreatitis (AP) accounts over the 50% of all hospital admissions due to pancreatic diseases and still represent one of the most unpredictable disease of the digestive system. The incidence of AP in UK is 30–50/100,000/year which makes around 20,000 hospitalizations per year¹. However, the highest incidence of AP has registered in USA and Finland². In 2016, in Serbia, 2,768 patients were admitted to the hospital for AP treatment (male/female – 1,630/1,138), whereas 170 patients (male/female – 105/65) due to cystic lesions of the pancreas, which included 6.15% in overall morbidity³. Pancreatic pseudocysts (PPCs) account for 75% of the cyst lesions of the gland and they are the most common complication of AP and chronic pancreatitis^{4,5}. The incidence of PPCs is 10% to 20% of patients with AP and may be present in 20% to 40% of patients with chronic pancreatitis^{5,6}. According to the Atlanta 2012 revised classification, the PPC is an encapsulated collection of fluid with a well defined inflammatory wall, minimal or no necrosis, which often requires for maturation more than four weeks after the onset of an acute pancreatic episode⁷. This definition well distinguished PPCs from other entities in AP [acute peripancreatic fluid collections, acute necrotic collections, walled-off pancreatic necrosis (WOPN), and cystic neoplasms]. Necrosis is a region of necrotic pancreatic parenchyma and/or peripancreatic fat. Acute necrotic collections occur within 4 weeks, whereas WOPN persists for more than 4 weeks. WOPN develops only after acute necrotizing pancreatitis and can be intrapancreatic or extrapancreatic. WOPN contains nonliquid material with varying amounts of fluid and has an encapsulating wall. Most PPCs with a diameter < 4 cm will resolve spontaneously, or will remain clinically stable without further complications. PPCs with a diameter between 4–6 cm can be managed by watchful waiting to see if they are asymptomatic or stable on follow-up radiological procedures. Sometimes, these PPCs can resolve spontaneously, but serious complications may occur in 10% of the cases. PPCs > 6 cm that are persistent more than 6

weeks should be treated by invasive approaches^{8,9}. In the last two decades, with continued improvements in medical technology and knowledge regarding treatment options in AP¹⁰, treatment of PPCs dramatically changed. From the traditionally open surgical internal drainage in the past, nowadays, less invasive options including percutaneous, endoscopic and laparoscopic drainage were increasingly reported¹¹. The morbidity and mortality rate have been reported as significantly lower for those minimally invasive approaches compared to open drainage surgical procedures^{10,11}. Unfortunately, in Serbia, minimally invasive approaches for the treatment of AP and its complications have implemented just a few years ago. In this case report, we presented the successful endoscopic transgastric drainage of the large PPC developed as a complication of AP.

Case report

A 63-years old male patient was admitted in our hospital due to nausea and vomiting as a consequence of the compressive effects of the PPC in the body and tail of the pancreas. Ultrasound on admission showed the large PPC with more than 15 cm in diameter. Two years ago, the patient was conservatively treated in another hospital due to alcoholic AP and he was discharged with a small acute fluid collection and small unilateral pleural effusion. On admission in our hospital, he was weak, malnourished, dehydrated with palpable painful tumefaction in the stomach region. Laboratory findings showed moderate inflammation with C-reactive protein of 54 mg/L, erythrocyte sedimentation rate of 60 mm/hour, leucocytes of $12.5 \times 10^9/L$, hemoglobin of 10.3 g/dL, platelets of $237 \times 10^9/L$, serum albumin level of 27 g/L and serum iron of 30 $\mu\text{mol/L}$ with normal serum levels of amylases, lipases, CA 19-9 and liver enzymes including aminotransferases and gamma-glutamyltransferase. On computed tomography (CT) scan (Toshiba Aquilion 64[®]), it was shown a cystic formation in the region of the pancreatic body and tail compressing stomach which was verified on upper endoscopy (Figure 1).

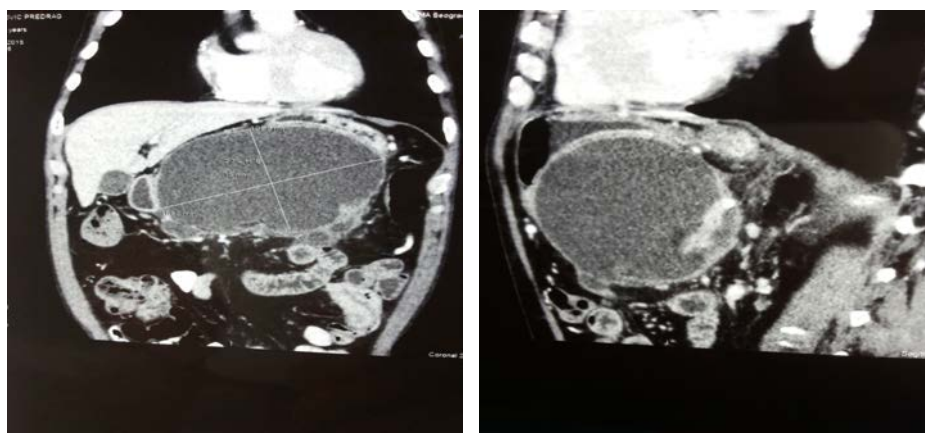


Fig. 1 – Computed tomography (CT) scan with the pancreatic pseudocyst (PPC) in the region of pancreatic body and tail.

Due to clinical condition of the patient (persisting vomiting, delayed gastric emptying and inability for normal food intake), it was decided that minimally invasive PPC drainage should be performed after initial resuscitation. Under fluoroscopy, using lateral duodenoscope (Pentax ED® 3490TK working channel 4.2), a incision on the posterior wall of the stomach was made, afterwards dilatation of the incision whole with biliary balloon diameter and length of 6 mm and 4 cm, respectively. After dilatation, the plastic biliary prosthesis of 12 French and 8 cm of length was placed throughout posterior stomach wall into the PPC (Figures 2 and 3).

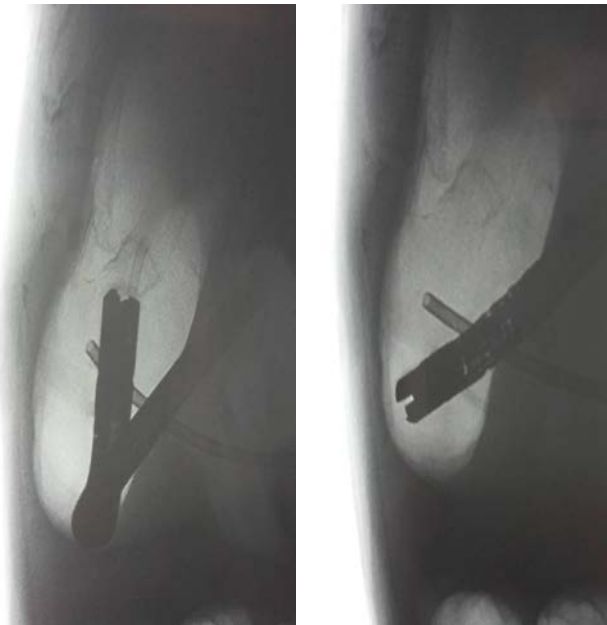

Fig. 2 – Placement of biliary stent under fluoroscopy.

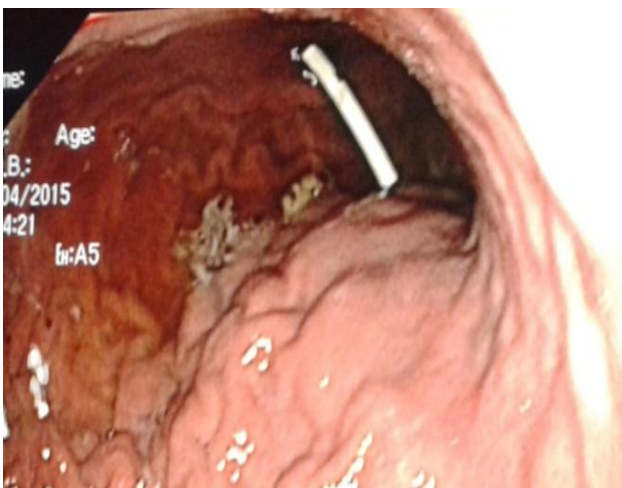

Fig. 3 – Upper endoscopy after placement of the prosthesis.

The intervention was finished uneventfully, without complications. The control abdominal ultrasound showed the reduction of the PPC size, the day after the procedure (Figure 4).

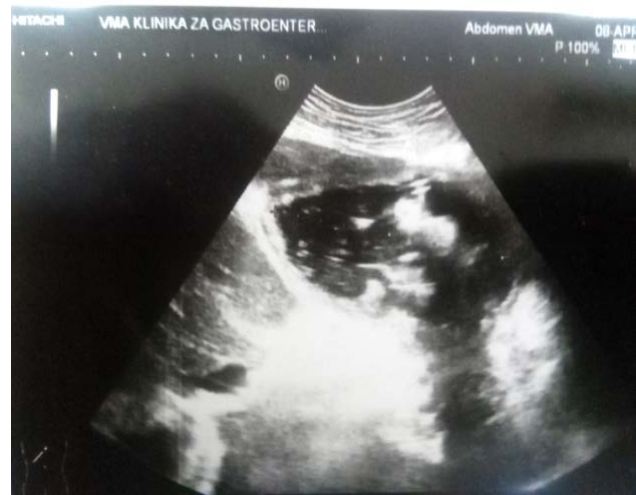

Fig. 4 – Abdominal ultrasound, the day after the procedure.

On the same day after the procedure, the patients started to take liquids and, on the next day, normal food and oral nutritional supplements for the improvements of nutritional status. On CT scan performed 7 days after the procedure, a size of the PPC was decreased for 7–8 cm in diameter (Figure 5).

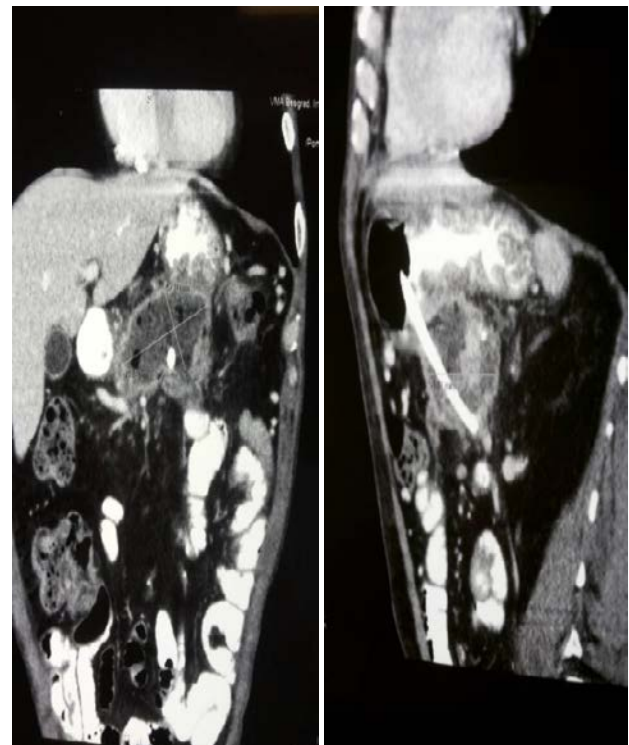

Fig. 5 – Computed tomography (CT) scan, one week after the procedure.

All laboratory findings including parameters of inflammation, blood cells count and serum amylase and lipase levels were in normal ranges one month after the procedure. Control CT scan, performed one month after the procedure and after removal of the prosthesis, showed almost

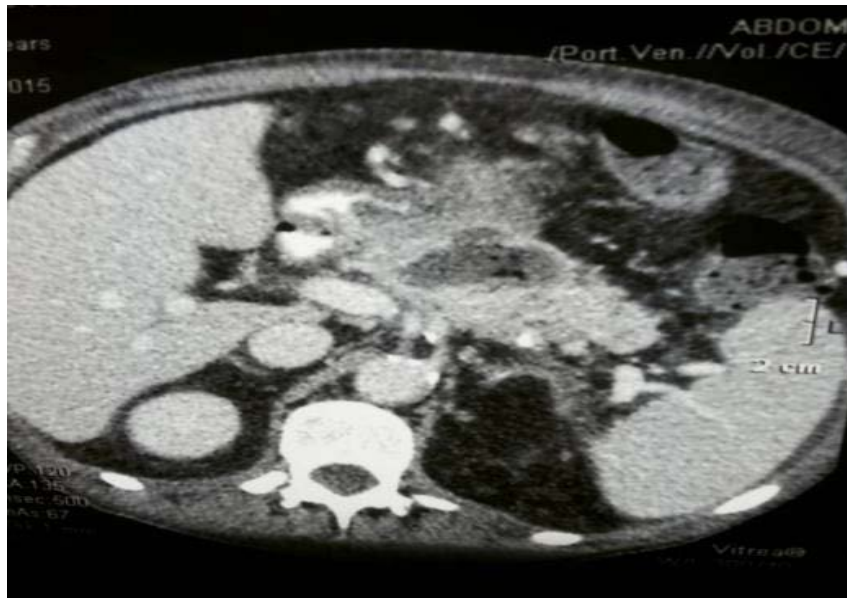

Fig. 6 – Computed tomography (CT) scan, one month after the procedure and prosthesis removal.

complete resolution of the PPC (Figure 6). The patient had no further complaints on follow-up conducted 3 months after the procedure.

Discussion

Based on the Atlanta revision⁷, the acute pancreatic collections need to be managed by drainage when there is abdominal pain, gastrointestinal and/or biliary obstruction, infection and if the size of the collection is greater than 5 cm in diameter. In a recently published review it was suggested that only symptomatic pancreatic collections should be managed, regardless their size¹². In addition to other minimally invasive procedures for pancreatic collections management, in the last decade endoscopic approach has increasingly been used. Currently, endoscopic drainage is recommended as the first-line treatment for accessible PPCs because it can provide excellent results in terms of costs, duration of hospital stay, and quality of life, as demonstrated in a recent prospective randomized study¹³.

A single case and the first reported case of endoscopic transgastric aspiration of a PPC was reported in 1975 by Rogers et al. Coworkers¹⁴. In the next decade only two reports described this procedure^{15, 16}. Kozarek et al.¹⁶ attempted cutting the bulging gastric wall with a needle-knife in 4 patients and reported the first nasocystic tube insertion in 1985. Over the next decade, the procedure was standardized, and retrospective studies proved the safety and efficacy of endoscopic PPC drainage with plastic stents. After introduction of endoscopic retrograde cholangiopancreatography (ERCP) in hepatobiliary and pancreatic pathology management, this procedure was used for PPC drainage¹⁷. However, there are only few indications for the transpapillary (ERCP) drainage of PPC¹⁸. It is important to mention that endoscopic drainage of PPC which

does not compress the stomach is relatively difficult to perform due to uncertain region of the posterior wall of the stomach for initial incision. Indeed, in 42-48% of PPCs, there is no evidence of propulsion or compressive effects of PPC on the posterior stomach wall¹⁹. This problem has been overridden by introduction of endoscopic ultrasound (EUS) which may measure a distance between PPC and posterior wall of the stomach with visible adjacent vessels and solid and/or necrotic pancreatic masses. The first endoscopic drainage of PPC was reported by Grimm et al. in 1992²⁰. After this report, the subsequent studies were conducted to evaluate a difference between EUS guided and conventional endoscopic PPC drainage. In a study of Kahaleh et al.²¹, it was concluded that both techniques have similar efficiency and complications rate in PPC drainage if conventional endoscopic procedure was performed in patients with evident compressive effects on stomach by the PPC and EUS guided drainage if there were no propulsion on stomach wall. In two randomized control trials, it was shown better successful rate and lower complications in EUS guided PPC drainage versus conventional technique, but without significant difference between techniques^{22, 23}. The first meta analysis regarding management of PPC was shown that surgical treatment had successful rate of 100% and the lowest recurrence rate (6-8.5%). However, the mortality rate was 1-8%. In contrast, endoscopic drainage had successful rate of 90-94%, recurrence rate of 12%, but mortality rate of 0%²⁴. Subsequent study showed that EUS guided PPC drainage should be the first line treatment of this pathology because it has had lower hospital costs and lower hospitalization time as compared to the open surgical approach²⁵. In recent review, it was concluded that EUS guided drainage is advantageous in drainage of PPC located adjacent to the stomach or duodenum. In patients with unfavorable anatomy, surgical approach or percutaneous drainage need to be

considered¹¹. One of the most challenge conditions for management represents PPC and pancreatic duct disruption. In suspected pancreatic duct disruption, ERCP and/or magnetic resonance cholangiopancreatography should be performed to evaluate the potential lesion of main pancreatic duct and eventual communication with PPC. Nealon et al.^{9,26} reported that altered anatomy of the main pancreatic duct has been associated with lower rate of PPCs resolution. In the follow up of 563 patients, they noticed that spontaneous resolution of PPCs was observed in 87% of patients with normal pancreatic duct versus no resolution in 5% of patients who had pancreatic duct disruption²⁶. In addition to this, it is important to evaluate the communication between PPCs and main pancreatic duct due to decrease rate of success after transgastric drainage in cases if this communication is present. Trevino et al.²⁷ found a reduce rate of successful endoscopic transgastric drainage versus simultaneous endoscopic transgastric and transpapillary drainage (80% versus 97.5%). This combined approach has not had increased mortality rate, length of hospitalization and necessity for additional necrosectomy regarding ERCP.

Overall clinical success of endoscopic transgastric PPC drainage with or without EUS ranges from 33–100%. It is suggested that ultrasound and/or CT scan should be performed after prosthesis placement every one or two months until PPC resolution, or earlier in case of symptoms and complications of the procedure. Following procedure, the complications occurs in around 15–64% of patients, and mortality rate ranges 0–19.6%. The most frequent complications are perforation and bleeding found to be more frequent in endoscopic transgastric drainage without EUS (13.3%) than in other approaches including surgery^{11, 28}. Although it is generally advisable to use plastic biliary “pig-tail” prostheses of 7.5 French, in our case we used prosthesis of 12 French with a length of 8 cm due to better drainage of PPC. In the current literature there is no reports regarding usage of classic biliary plastic prosthesis for the PPCs drainage. In several studies with 698 patients observed, a significant difference in clinical success, mortality and recurrence rate after endoscopic PPCs drainage using various

and multiple plastic or metal prosthesis were not found^{29, 30}. However, one study showed that drainage of PPCs with plastic prosthesis had 2.5 higher complication rate versus drainage using metal stents. Also, complete resolution of PPCs after drainage was higher after metal stents versus plastic prosthesis (98% versus 89%)³¹. Our case is the first presented one of transgastric endoscopic PPC drainage in Serbia and maybe the first one in whom drainage of PPC was performed with plastic prosthesis with 12 French and 8 cm length.

In addition to the established implementation of minimally invasive / “step-up” approach for the treatment of patients with AP in Western countries, our country and maybe the region are lagging behind. Possible reason for this is lack of technical support and relative insufficient trained staff for this kind of treatment. Although there is lacking of data in trials comparing different minimally invasive techniques for management of patients with AP, this kind of treatment has shown overall better results as comparing to the traditionally open surgical approach^{7, 8, 10, 11, 18}. In order to have better treatment quality and better care of patients with AP, including lower morbidity, length of hospitalization, treatment costs and quality of patients’ life, we need to implement “step-up” approach in a routine medical practice. This will include percutaneous drainage (transperitoneal and retroperitoneal), endoscopic transgastric drainage with or without EUS, videoscopic assisted retroperitoneal debridement and laparoscopic approach.

Conclusion

Endoscopic drainage is safe and effective procedure for PPCs especially when the PPC has propulsion effects on the stomach wall. Transgastric drainage of PPCs with endoscopic ultrasound increases reliability and safety. For adequate treatment, a careful evaluation of patients in multidisciplinary team, including imaging specialists, dedicated interventional gastroenterologists and radiologists, and pancreatic surgeons is essential.

R E F E R E N C E S

1. National Institute for Health and Care Excellence. Pancreatitis. Pancreatitis diagnosis and management: Nice guideline. [cited 2018 March]. Available from: <https://www.nice.org.uk/guidance/ng104/documents/draft-guideline>
2. Banks PA. Epidemiology, natural history, and predictors of disease outcome in acute and chronic pancreatitis. *Gastrointest Endosc* 2002; 56(6 Suppl): S226–30.
3. Institute of Public Health of Serbia. "Dr. Milan Jovanovic Batut". Hospitalization report for 2016. Belgrade: Republic Institute of Statistics; 2017. (Serbian)
4. Aghdassi AA, Mayerle J, Kraft M, Sielenkämper AW, Heidecke CD, Lerch MM. Pancreatic pseudocysts--when and how to treat? *HPB (Oxford)* 2006; 8(6): 432–41.
5. Kim KO, Kim TN. Acute pancreatic pseudocyst: incidence, risk factors, and clinical outcomes. *Pancreas* 2012; 41(4): 577–81.
6. Song TJ, Lee SS. Endoscopic drainage of pseudocysts. *Clin Endosc* 2014; 47(3): 222–6.
7. Banks PA, Bollen TL, Dervenis C, Gooszen HG, Johnson CD, Sarr MG, et al. Acute Pancreatitis Classification Working Group. Classification of acute pancreatitis--2012: revision of the Atlanta classification and definitions by international consensus. *Gut* 2013; 62(1): 102–11.
8. Beyer G, Mayerle J, Lerch MM. Strategies for the Treatment of Pancreatic Pseudocysts and Walled-Off Necrosis After Acute Pancreatitis: Interventional Endoscopic Approaches. In: *Begger HG, Warsaw AL, Hruban RH, Buchler MW, Lerch MM, Neoptolemos JP*, et al, editors. *The Pancreas: An Integrated Textbook of Basic Science, Medicine, and Surgery*. 3rd ed. Hoboken, New Jersey: Wiley Blackwell Publishing Limited; 2018.
9. Nealon WH, Walser E. Main pancreatic ductal anatomy can direct choice of modality for treating pancreatic pseudocysts

- (surgery versus percutaneous drainage). *Ann Surg* 2002; 235(6): 751–8.
10. *van Santvoort HC, Besselink MG, Bakker OJ, Hofker HS, Boermeester MA, Dejong CH*, et al. Dutch Pancreatitis Study Group. A step-up approach or open necrosectomy for necrotizing pancreatitis. *N Engl J Med* 2010; 362(16): 1491–502.
 11. *Teoh AY, Dhir V, Jin ZD, Kida M, Seo DW, Ho KY*. Systematic review comparing endoscopic, percutaneous and surgical pancreatic pseudocyst drainage. *World J Gastrointest Endosc* 2016; 8(6): 310–8.
 12. *Tyberg A, Karia K, Gabr M, Desai A, Doshi R, Gaidhane M*, et al. Management of pancreatic fluid collections: A comprehensive review of the literature. *World J Gastroenterol*. 2016; 22(7): 2256–70.
 13. *Varadarajulu S, Bang JY, Sutton BS, Trevino JM, Christein JD, Wilcox CM*. Equal Efficacy of Endoscopic and Surgical Cystgastrostomy for Pancreatic Pseudocyst Drainage in a Randomized Trial. *Gastroenterology* 2013; 145(3): 583–90.e1.
 14. *Gerald BH, Cicirel NJ, Seed RW*. Transgastric needle aspiration of pancreatic pseudocyst through an endoscope. *Gastrointest Endosc* 1975; 21(3): 133–4.
 15. *Khawaja FI, Goldman LP*. Endoscopic drainage of a pancreatic pseudocyst and pseudo-gastric fistulae. *Gastrointest Endosc* 1983; 29: 171.
 16. *Kozarek RA, Brayko CM, Harlan J, Sanonski RA, Cintora I, Kovac A*. Endoscopic drainage of pancreatic pseudocysts. *Gastrointest Endosc* 1985; 31(5): 322–8.
 17. *Keil R, Námesný I, Drábek J, Martinek J, Hořák J, Janík V*. Endoskopická drenáž pankreatických pseudocyst. *Miniinvaz. Terapie* 1997; 5: 34–6. (Czech)
 18. *Howell D, Saltzman J, Robson K*. Endoscopic management of walled-off pancreatic fluid collections: Techniques. 2017. Available from: <https://www.uptodate.com/contents/endoscopic-management-of-walled-off-pancreatic-fluid-collections-techniques>.
 19. *Antillon MR, Shah RJ, Stiegmann G, Chen YK*. Single-step EUS-guided transmural drainage of simple and complicated pancreatic pseudocysts. *Gastrointest Endosc* 2006; 63(6): 797–803.
 20. *Grimm H, Binmoeller KF, Soebendra N*. Endosonography-guided drainage of a pancreatic pseudocyst. *Gastroint Endosc* 1992; 38(2): 170–1.
 21. *Kahaleh M1, Shami VM, Conaway MR, Tokar J, Rockoff T, De La Rue SA*, et al. Endoscopic Ultrasound Drainage of Pancreatic Pseudocyst: A Prospective Comparison with Conventional Endoscopic Drainage. *Endoscopy* 2006; 38(4): 355–9.
 22. *Varadarajulu S, Christein JD, Tambane A, Drelichman ER, Wilcox CM*. Prospective randomized trial comparing EUS and EGD for transmural drainage of pancreatic pseudocysts (with videos). *Gastrointest Endosc* 2008; 68(6): 1102–11.
 23. *Park DH, Lee SS, Moon SH, Choi SY, Jung SW, Seo DW*, et al. Endoscopic ultrasound-guided versus conventional transmural drainage for pancreatic pseudocysts: a prospective randomized trial. *Endoscopy* 2009; 41(10): 842–8.
 24. *Vosoghi M, Sial S, Garrett B, Feng J, Lee T, Stabile BE*, et al. EUS-guided pancreatic pseudocyst drainage: review and experience at Harbor-UCLA Medical Center. *MedGenMed* 2002; 4(3): 2.
 25. *Varadarajulu S, Lopes TL, Wilcox CM, Drelichman ER, Kilgore ML, Christein JD*. EUS versus surgical cyst-gastrostomy for management of pancreatic pseudocysts. *Gastrointest Endosc* 2008; 68(4): 649–55.
 26. *Nealon WH, Bhutani M, Riall TS, Raju G, Ozkan O, Neilan R*. A Unifying Concept: Pancreatic Ductal Anatomy Both Predicts and Determines the Major Complications Resulting from Pancreatitis. *J Am Coll Surg* 2009; 208(5): 790–9; discussion 799–801.
 27. *Trevino JM, Tambane A, Varadarajulu S*. Successful stenting in ductal disruption favorably impacts treatment outcomes in patients undergoing transmural drainage of peripancreatic fluid collections. *J Gastroenterol Hepatol* 2010; 25(3): 526–31.
 28. *Fockens P, Johnson TG, van Dullemen HM, Huibregtse K, Tytgat GN*. Endosonographic imaging of pancreatic pseudocysts before endoscopic transmural drainage. *Gastrointest Endosc* 1997; 46(5): 412–6.
 29. *Melman L, Azar R, Beddow K, Brunt LM, Halpin VJ, Eagon JC*, et al. Primary and overall success rates for clinical outcomes after laparoscopic, endoscopic, and open pancreatic cystgastrostomy for pancreatic pseudocysts. *Surg Endosc* 2009; 23(2): 267–71.
 30. *Navaneethan U, Njei B, Sanaka MR*. 734 Endoscopic Transmural Drainage of Pancreatic Pseudocysts: Multiple Plastic Stents Versus Metal Stents- a Systematic Review and Meta-Analysis. *Gastrointest Endosc* 2014; 79(5): AB167–8.
 31. *Sharaiha RZ, DeFilippis EM, Kedia P, Gaidhane M, Boumitri C, Lim H*, et al. Metal versus plastic for pancreatic pseudocyst drainage: clinical outcomes and success. *Gastrointest Endosc* 2015; 82(5): 822–7.

Received on July 23, 2018.

Revised on December 24, 2018.

Accepted on December 3, 2018.

Online First January, 2019.